LETTER FROM THE FRONTLINE

First Description of Single-Pass Albumin Dialysis Combined With Cytokine Adsorption in Fulminant Liver Failure and Hemophagocytic Syndrome Resulting From Generalized Herpes Simplex Virus 1 Infection

Received September 4, 2014; accepted September 12, 2014.

TO THE EDITORS:

Acute liver failure (ALF) is a rare, life-threatening complication of herpes simplex virus (HSV) infection that can occur in immunocompetent patients. Liver transplantation (LT) is the ultima ratio in cases of ALF that progress despite antiviral treatment.[1] To bridge the time until LT, extracorporeal liver support with the Molecular Adsorbent Recirculating System (MARS; Gambro, Lund, Sweden) has been shown to be a therapeutic option in ALF.[2] Data concerning the use of single-pass albumin dialysis (SPAD) in such cases, however, are scarce.[3] Hemophagocytic lymphohistiocytosis (HLH) is a severe hyperinflammatory syndrome that can occur in many underlying conditions.[4] Animal studies, case reports, and preliminary data from a clinical trial in septic patients have demonstrated that a reduction in blood cytokine levels achieved with an extracorporeal cytokine adsorption cartridge that contains blood-compatible porous polymer beads (CytoSorb, Monmouth Junction, NJ) can effectively attenuate the inflammatory response during sepsis and possibly improve outcomes.[5,6]

CASE REPORT

A 50-year-old immunocompetent woman was admitted to our hospital for acute hepatitis with ALF. Transjugular biopsy of the liver showed acute liver cell necrosis. HSV1 was identified as the causative agent, and intravenous antiviral therapy with acyclovir was initiated. As her liver failure progressed, the patient was transferred to the intensive care unit. She rapidly developed multiorgan dysfunction syndrome with hepatic coma, severe coagulopathy, acute anuric renal failure, respiratory insufficiency, and arterial hypotension. The patient was listed on Eurotransplant for highly urgent LT. Hyperferritinemia up to 266,000 μg/L (normal range = 13-300 μg/L) with pancytopenia and a high plasma level of the soluble interleukin-2 (IL-2) receptor (6815 U/mL; normal range = 223-710 U/mL) raised suspicion of secondary virus-associated HLH. Bone marrow biopsy was performed. The histological examination showed a high number of activated macrophages that incorporated erythrocytes and granulocytes, and this supported the diagnosis of HLH secondary to HSV1 infection.

Hemodialysis and extracorporeal liver support were initiated with MARS therapy for 6 hours on the first day and for 19 hours on the second day. Worsening circulatory failure with an increasing need for norepinephrine (maximum = 0.6 μg/kg/minute) and excessively elevated concentrations of inflammatory markers (IL-6 and ferritin) indicated ongoing, severe systemic inflammatory response syndrome. The extracorporeal therapy was thus changed to continuous venovenous hemodialysis, with SPAD performed with a standard hemodialysis machine for continuous therapy (Multifiltrate, Fresenius Medical Care, Bad Homburg, Germany) and a high-flux polysulfone membrane (Ultraflux AV1000S, Fresenius Medical Care). The standard dialyzing solution (multiBIC, Fresenius Medical Care) was enriched with 20% human albumin to a final concentration of 2% albumin (dialysate flow = 1500 mL/hour; 12 hours of treatment). After 12 hours of SPAD, standard continuous venovenous hemodialysis was continued. A hemoadsorption cartridge (CytoSorb) was integrated into a predialyzer position (total treatment duration = 20 hours) to promote cytokine adsorption. Regional anticoagulation was performed with sodium citrate. The IL-6 concentration before treatment was 81,059 pg/mL (normal range < 7.00 pg/mL). After 12 hours of treatment, it had fallen to 17,177 pg/mL. The norepinephrine dosage could be reduced to 0.25 μg/kg/minute. Clinically, no further deterioration of the patient's

Address reprint requests to Silvius Frimmel, M.D., Division of Nephrology, Department of Medicine, Rostock University Medical Center, Ernst-Heydemann-Strasse 6, D-18057 Rostock, Germany. Telephone: 49-381-494-7511; FAX: 49-381-494-7509; E-mail: silvius.frimmel@med.uni-rostock.de

DOI 10.1002/lt.24005
View this article online at wileyonlinelibrary.com.
LIVER TRANSPLANTATION. DOI 10.1002/lt. *Published on behalf of the American Association for the Study of Liver Diseases*

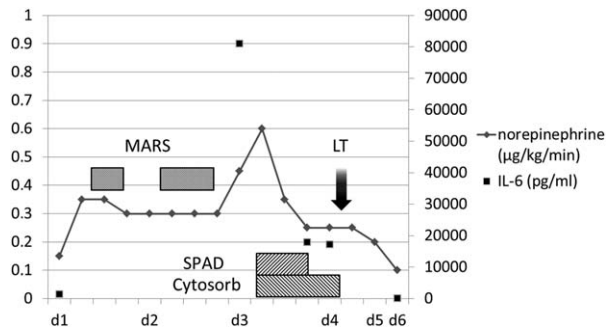

Figure. 1. Dosage of norepinephrine and plasma levels of IL-6 under therapy.

condition was seen. Interestingly, during the combined treatment with SPAD and CytoSorb, a reduction in the patient's moderately elevated bilirubin concentration was achieved, whereas a slight increase was observed during MARS therapy. Successful orthotopic LT was performed on the fourth day of intensive care unit treatment. Two days after transplantation under immunosuppression with tacrolimus and prednisone, the plasma levels of ferritin and IL-6 decreased further to 7202 μg/L and 47.2 pg/mL, respectively (Fig. 1).

DISCUSSION

To the best of our knowledge, this is the first report of CytoSorb hemoadsorption being used in combination with SPAD in a patient suffering from ALF and probable HLH with severe systemic inflammatory response syndrome who was listed for LT. A marked decrease in IL-6 and bilirubin and a reduction in the need for vasopressor use were the main results of this intervention. By removing or reducing proinflammatory cytokines to correct the systemic inflammatory response and by providing detoxification, cytokine adsorption might be a useful tool in the management of ALF and severe hyperinflammatory syndromes such as HLH. The treatment was safe and well tolerated without any adverse events. Multicenter experiences and studies are needed to confirm the benefit of this treatment.

Silvius Frimmel, M.D.[1]
Jan Schipper, M.D.[1]
Joerg Henschel, M.D.[2]
Tung Yu Tsui, M.D., Ph.D.[3]
Steffen R. Mitzner, M.D., Ph.D.[1,4]
Sebastian Koball, M.D.[1]
[1]Division of Nephrology, Department of Medicine,
[2]Intensive Care Unit, Department of Medicine, and
[3]Section of Oncological Surgery and Transplantation
Rostock University Medical Center
Rostock, Germany
[4]Extracorporeal Immunomodulation Unit
Fraunhofer Institute for Cell Therapy and Immunology
Rostock, Germany

REFERENCES

1. Norvell JP, Blei AT, Jovanovic BD, Levitsky J. Herpes simplex virus hepatitis: an analysis of the published literature and institutional cases. Liver Transpl 2007;13: 1428-1434.
2. Saliba F, Camus C, Durand F, Mathurin P, Letierce A, Delafosse B, et al. Albumin dialysis with a noncell artificial liver support device in patients with acute liver failure: a randomized, controlled trial. Ann Intern Med 2013;159:522-531.
3. Karvellas CJ, Bagshaw SM, McDermid RC, Stollery DE, Bain VG, Gibney RT. A case-control study of single-pass albumin dialysis for acetaminophen-induced acute liver failure. Blood Purif 2009;28:151-158.
4. Janka GE, Lehmberg K. Hemophagocytic syndromes—an update. Blood Rev 2014;28:135-142.
5. Peng ZY, Carter MJ, Kellum JA. Effects of hemoadsorption on cytokine removal and short-term survival in septic rats. Crit Care Med 2008;36:1573-1577.
6. Mitzner SR, Gloger M, Henschel J, Koball S. Improvement of hemodynamic and inflammatory parameters by combined hemoadsorption and hemodiafiltration in septic shock: a case report. Blood Purif 2013;35:314-315.